

Post-LASIK Ectasia Management

UVA collagen cross-linking plus topography-guided PRK is an efficient way to avoid corneal transplantation in post-LASIK ectasia patients.

BY A. JOHN KANELLOPOULOS, MD

A 29-year-old patient underwent unioocular LASIK for the correction of myopic astigmatism 3 years ago. His initial UCVA was 20/80, and his BSCVA was 20/20 with a refraction of -2.00 -1.75 X 85. Three months post-LASIK, he began experiencing regression with myopia and astigmatism to the point of UCVA 20/200 and BSCVA 20/80 with a refraction of -3.50 -2.00 X 120.

Based on irregular topography and the loss in BSCVA, the treating physician soon recognized that a mechanism of ectasia¹⁻³ had begun. Because this was not functionally correctable with spectacles or contact lenses, the decision was made to implant intracorneal ring segments for the management of this complication. Unfortunately, the patient's UCVA remained 20/200, and his was BSCVA 20/100.

The treating surgeon recommended cornea transplantation as the next step. My initial evaluation of the patient was made 11 months post-LASIK and 3 months after intracorneal ring implantation. His corneal topography is shown in Figure 1. Corneal thickness — by Orbscan (Bausch & Lomb, Rochester, NY) and ultrasound pachymetry — was 410 μm at the thinnest point, and the endothelial cell count was 2,750 cells per mm^2 (Noncon Robo; Konan Medical, Hyogo, Japan).

OPTIONS FOR TREATMENT

We have had poor long-term outcomes with intracorneal ring segments in post-LASIK ectasia,^{4,5} a fact that was discussed with the patient as well as the benefits and risks of corneal transplant and combined UV radiation and riboflavin treatment in order to achieve collagen cross-linking and biomechanical stabilization of the corneal ectasia. We then obtained patient consent to remove the failed intracorneal ring segments.

I treated the patient's cornea with a single application of UVA radiation at 3 mW/cm^2 for 30 minutes (KeraCure;

Priavisio, Menlo Park, Calif) combined with 0.1% riboflavin ophthalmic solution in 20% dextran T-500. This treatment was performed after removing the corneal epithelium with 20% EtOH placed on the surface for 30 seconds. The riboflavin solution, applied for about 2 minutes, soaked the stromal bed and protected the iris, crystalline lens and retina from UV irradiation. One drop every 2 minutes was applied during the irradiation.

A bandage contact lens was placed on the cornea for 5 days, and the patient was treated with topical ofloxacin 1% (Ocuflox; Allergan, Irvine, Calif) and prednisolone acetate 1% (Predforte, Allergan) four times a day for 10 days. The bandage contact lens was removed at day 4, following complete reepithelialization.

IMPROVEMENT IN VISUAL ACUITY

At 3 months, the patient's UCVA improved from 20/400 to 20/70, and his BSCVA improved from 20/200 to 20/40. The refraction changed from -4.50 -4.50 X 120 to -4.50 -4.00 X 115, and corneal topography changed as seen in Figure 1B. The stability of these parameters and the corneal topography between months 1 and 3 of this treatment encouraged us to proceed with topography-guided PRK. We sought to reduce the irregular astigmatism and attempted to provide the patient with visual acuity not requiring spectacle or soft contact lens correction.

Because the patient's corneal thickness was 410 μm , we were able to treat his full spectacle correction using the Allegretto Wave excimer laser (Wavelight Laser Technologie AG, Erlangen, Germany) topography-guided customized ablation treatment (T-CAT) software. After placing 20% dilution of EtOH on the corneal surface for 30 seconds and subsequent epithelium removal, I performed laser treatment. A bandage contact lens was placed for 5 days, and the patient was retreated with ofloxacin and prednisolone four times a day for 10 days. The bandage contact lens was removed at day 4, following complete reepithelialization.

One month after topography-guided treatment, the patient's UCVA was 20/20-, and his BSCVA was 20/20 with a refraction of +0.50 -5.0 X 160. The corneal endothelium count had remained stable at 2,700 cells per mm². The patient complained of night vision symptoms of halos and ghosting. He is now at 34 months postoperative and has a UCVA of 20/20 with some mild night vision problems and corneal topography as shown in Figure 1. One can also appreciate the difference map between pre and post-topography-guided treatment in Figure 1D, as well as the actual ablation profile that was used for the treatment in Figure 1.

TREATMENT OF IATROGENIC KERATECTASIA

Different techniques have been suggested for the treatment of iatrogenic keratectasia without satisfactory outcomes either biomechanically or visually, with the patient's journey most frequently ending with penetrating corneal graft.⁶⁻¹¹ Reports of the use of riboflavin/UVA corneal cross-linking have been shown to slow down keratoconus¹²⁻¹⁴ and progressive iatrogenic ectasia.¹⁵ During the past 3 years, we have had extensive experience with customized topography-guided excimer ablations that we have presented and reported.¹⁶ This customized approach can, in our opinion, address the extreme cornea irregularity that these cases may have and enhance visual rehabilitation.

To our knowledge, this is the first report of post-LASIK ectasia treatment using a combination of UVA collagen cross-linking to stabilize the corneal biomechanics, followed by surface excimer laser ablation for visual rehabilitation. Remarkable corneal stabilization, together with full visual rehabilitation, leads us to believe that this approach may have a wider application in the near future.

Considering the burden on the patient in everyday life, as well as the medical-legal issues involved in such a complica-

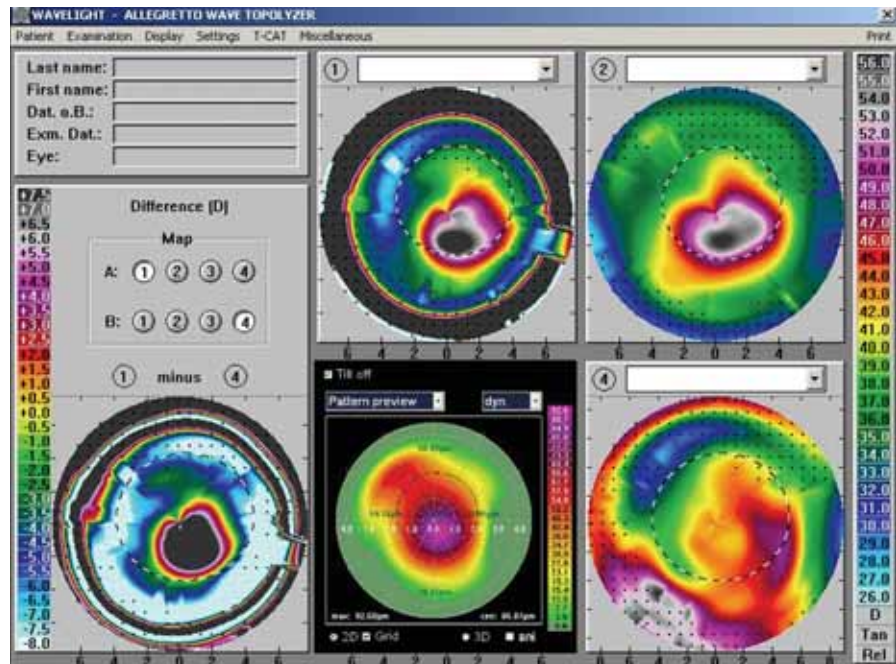


Figure 1. This display of topographies depicts the following: (A) Central cornea ectasia and mid-periphery flattening. At this point, BSCVA was 20/200. (B) Two months following the removal of intacs and 1 month following UVA collagen cross-linking. The central steepening is still present and the effect of the intacs removal is appreciated. At this point, BSCVA was 20/200. (C) The lower row image in the center is an estimated cornea topographic ablation pattern as a laser treatment plan of the topography-guided procedure. It is notable that this ablation pattern is highly irregular with deeper ablation plan just inferiorly and right to the center, that matches though the central cornea irregularity in the previous topographies. (D) Six months following topography-guided PRK, the central cornea appears more regular and flatter. At this point, BSCVA and UCVA is 20/20-. (E) The lower row image on the left is a comparison map. This map depicts the difference of subtracting the cornea topography 4 (final result) from the cornea topography 1 (original state of this complication when encountered by us). The difference resembles impressively the topography-guided ablation pattern (next image to the right) demonstrating effectively the specificity of this treatment in reducing the pathogenic cornea irregularity, which we theorize that contributed in the drastic improvement of BSCVA.

tion of elective excimer laser refractive surgery as iatrogenic keratectasia, we feel that the combined procedure discussed here is now a valuable alternative to therapeutic cornea transplantation¹⁷ and should be considered in any case that enables the application of this treatment.

MINIMAL CORNEAL THICKNESS

Special emphasis must be taken to ensure minimal corneal thickness preoperatively because of potential cytotoxic effects of UVA on corneal endothelial cells. Previous experimental studies in rabbit corneas have investigated dose-dependent cytotoxicity to the corneal endothelium.

(Continued on page 62)

(Continued from page 43)

amount of negative feedback regarding overall vision, though, have been those who received the Crystalens. In our experience, more patients complain about glare and halos with multifocals than with the Crystalens. Results from FDA trials demonstrated similar findings concerning the increased inducement of glare and halos with multifocals as well.

PATIENT SELECTION

When considering which IOL to implant in a particular individual, careful patient selection is key to achieving successful postoperative results. In general, if the patient needs good J1 near vision, my colleagues and I lean toward implanting the Acrysof Restor. If there has been a rupture in the posterior capsule or a tear in the anterior capsule, or if there is zonular weakness, a multifocal may, again, be a better option. Additionally, the multifocals are the only choice for sulcus implantation. If it is a patient who needs more of a bifocal effect, we look at multifocals.

We choose the Crystalens for patients who desire more intermediate vision and the clarity of the distance vision. The Crystalens offers excellent quality of vision and is often our choice for more active patients. Intermediate vision is important to most patients today considering the high levels of cell phone, computer and PDA usage.

Not only does patient selection play a role, but it is necessary to perform careful individual eye assessments. In certain cases, it may be appropriate to mix accommodating and multifocal IOLs in order to achieve the optimal result. In contrast, a monofocal lens remains the best solution for some patients.

FUTURE MODIFICATIONS

Presently, trials are being conducted for several newer generation accommodative lenses, such as the Akkommodative 1CU (Human Optics, Erlangen, Germany), with reportedly favorable preliminary results. Additionally, Eyeonics is working on various improvements that it will plan to integrate into its Crystalens technology, with the aim of increasing accommodation and further improving the quality of near vision. With these advancements, accommodative lenses will surely be an option for many surgeons and patients. ■

Stephen G. Slade, MD, FACS, is in private practice in Houston. He states that he has consulted for Eyeonics. Dr. Slade may be reached at sgs@visiontexas.com or +1 713 626-5544.



(Continued from page 41)

These have clearly shown that surface irradiance, according to the protocol described herein, may not be used in corneas thinner than 350 µm. This minimal thickness should also be respected in human corneas.

The laser treatment must be applied with caution because more rigid corneas may have a different ablation depth-per-pulse than untreated corneas. It appears to result in overcorrections when these corneas are treated with an excimer laser versus a normal PRK or LASIK procedure. For this reason, our recommendation is to use 75% to 80% of the measured sphere and cylinder as a correction parameter when planning the ablation with T-CAT software.

Larger comparative studies and longer follow-up will validate the long-term efficacy of this treatment with UV/riboflavin followed by topography-guided excimer laser. The refractive and topographic stability over 1 year, however, appears to validate this minimally invasive treatment of iatrogenic keratectasia and leads us to believe that it may have an even wider application in the near future. ■

A. John Kanellopoulos, MD, practices at the Laservision Institute in Athens, Greece. He is an associate professor at the New York University Medical College and the Manhattan Eye, Ear and Throat Hospital, New York, NY. Dr. Kanellopoulos is a member of the CRSTODAY EUROPE Editorial Board and cosection editor of the refractive complications column. He did not provide financial disclosure information. He may be reached at laservision@internet.gr.



- Seiler T, Koufala K, Richter G. Iatrogenic keratectasia after laser in situ keratomileusis. *J Refract Surg.* 1998;14:312-317.
- Binder PS. Ectasia after laser in situ keratomileusis. *J Cataract Refract Surg.* 2003;29:2419-2429.
- Lifshitz T, Levy J, Klempere I, Levinger S. Late bilateral keratectasia after LASIK in a low myopic patient. *J Refract Surg.* 2005;21:494-496.
- Guell JL. Are intracorneal rings still useful in refractive surgery? *Curr Opin Ophthalmol.* 2005;16:260-265.
- Kanellopoulos AJ, Pe LH, Perry HD, Donnenfeld ED. Modified intracorneal ring segment implantation (INTACS) for the management of moderate to advanced keratoconus: efficacy and complications. *Cornea.* 2006;25:29-33.
- Hiatt JA, Wachter BS, Grant C. Reversal of laser in situ keratomileusis-induced ectasia with intraocular pressure reduction. *J Cataract Refract Surg.* 2005;31:1652-1655.
- Seiler T. [Iatrogenic corneal ectasia after LASIK-is the end in sight?] *Klin Monatsbl Augenheilkd.* 2005;222:429.
- Dupps Jr, WJ. Biomechanical modeling of corneal ectasia. *J Refract Surg.* 2005;21:186-190.
- Guirao A. Theoretical elastic response of the cornea to refractive surgery: risk factors for keratectasia. *J Refract Surg.* 2005;21:176-185.
- Toshino A, Uno T, Ohashi Y, et al. Transient keratectasia caused by intraocular pressure elevation after laser in situ keratomileusis. *J Cataract Refract Surg.* 2005;31:202-204.
- Alio JL, Claramonte PJ, Caliz A, Ramzy MI. Corneal modeling of keratoconus by conductive keratoplasty. *J Cataract Refract Surg.* 2005;31:190-197.
- Spoerl E, Seiler T. Techniques for stiffening the cornea. *J Refract Surg.* 1999;15:711-713.
- Wollensack G, Spoerl E, Seiler T. Riboflavin/ultraviolet-a-induced collagen crosslinking for the treatment of keratoconus. *Am J Ophthalmol.* 2003;135:620-627.
- Wollensack G, Spoerl E, Wilsch M, Seiler T. Endothelial cell damage after riboflavin-ultraviolet-A treatment in the rabbit. *J Cataract Refract Surg.* 2003;29:1786-1790.
- Hafezi F, Mrochen M, Jankov M, et al. Corneal collagen crosslinking with riboflavin/UVA for the treatment of induced keratectasia after laser in situ keratomileusis. In press.
- Kanellopoulos AJ. Topography-guided custom retreatments in 27 symptomatic eyes. *J Refract Surg.* 2005;21:S513-S518.
- Donnenfeld ED, Kanellopoulos AJ. Therapeutic Penetrating Keratoplasty. Chapter 150, Volume III. Pages 1843-1871. In: JH Krachmer, MJ Mannis, EJ Holland. *Cornea.* 1997 Mosby, St Louis, Mo.