

Bimanual Rhexis Using Capsulorrhexis Chopsticks

A new technique allows creation of the rhexis in the horizontal plane.

BY THIERRY AMZALLAG, MD; AND JOEL PYNSON, MD

Today, the major trend in cataract surgery is toward microincisions. Surgeons are reporting excellent results with sub-2-mm incisions, and some would argue that future techniques should inevitably use even smaller incisions. As we continue to transition to this era of cataract surgery, new technologies and techniques will complement the concepts of microincision cataract surgery (MICS) and micro-MICS. I have devised a new capsulorrhexis device, capsulorrhexis chopsticks (Figure 1; prototype made in conjunction with Bausch & Lomb, Heidelberg, Germany), that can be used through these reduced incision sizes.

The capsulorrhexis is the most important step of cataract surgery; however, the devices used for its creation are the limiting factor for a full transition to MICS and micro-MICS. Currently, surgeons have only the options of using a bent needle or forceps. Although the bent needle can be introduced through incisions as small as 1 mm, with this single-use instrument the surgeon has only bidimensional control of the tear. Additionally, the surgeon must use a cohesive ophthalmic viscosurgical device (OVD). With forceps, surgeons have tridimensional control of the capsulorrhexis and can use either a cohesive or dispersive OVD.

The capsulorrhexis is the most important step of cataract surgery; however, the devices used for its creation are the limiting factor for a full transition to MICS and micro-MICS.

However, capsulorrhexis forceps are fragile and need a larger incision due to their expansion after insertion.

The ideal capsulorrhexis device should be simple, inexpensive, and useable through incisions as small as sub-1-mm. It should produce a precise and reliable capsulotomy with a short learning curve. The technology should discourage OVD leakage from the incision and allow adequate space maintenance, even in a shallow anterior chamber. Additionally, it should maintain tridimensional control and create a large capsulorrhexis. I propose that a bimanual rhexis technique with capsulorrhexis chopsticks achieves these criteria.

BIMANUAL RHEXIS TECHNIQUE

To begin the bimanual rhexis, two sub-1-mm clear corneal incisions are made at the 10- and 2-o'clock positions (Figure 2A and B). A cohesive or dispersive OVD is

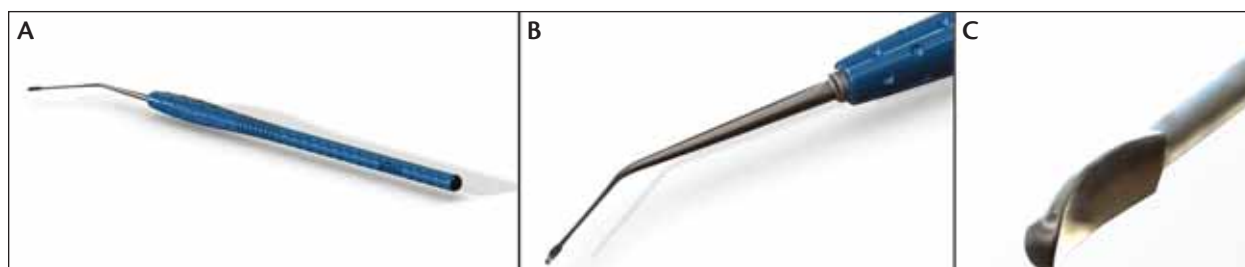


Figure 1. (A,B) Bimanual capsulorrhexis chopstick and (C) close-up of the tip of the device.

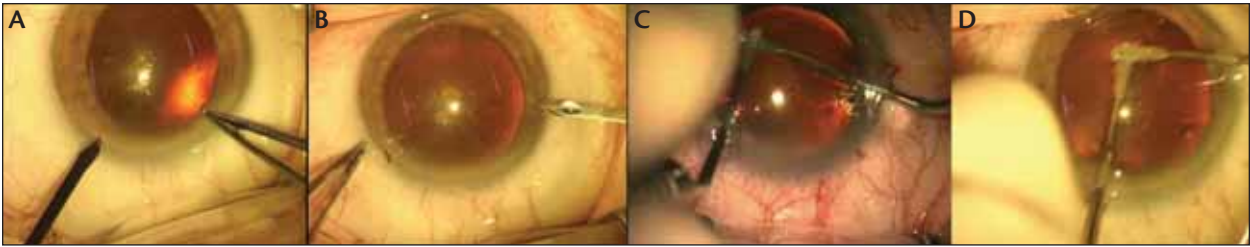


Figure 2. (A, B) Two 1-mm incisions are made at the 10- and 2-o'clock positions. (C) For the first half of the capsulorrhexis, the left chopstick is on top and the right one trails behind. (D) In the second half, the positions are reversed, with the right chopstick on top.

injected into the anterior chamber, and the capsulorrhexis is then constructed starting at approximately 12- or 10-o'clock at the desired capsulorrhexis diameter (approximately 5.5 mm). The two capsulorrhexis chopsticks are introduced through both incisions, and the capsular tear is initiated in the horizontal plane using a shearing technique. (In standard capsulorrhexis techniques, the tear is made in the vertical plane; this is the main difference between these techniques and the bimanual rhexis.)

The left chopstick is placed above the right one, directing the capsulorrhexis toward the 8- or 9-o'clock position (Figure 2C). The right device trails behind. After a bimanual transition at the 8-o'clock position, the second stage of the capsulorrhexis begins (Figure 2D). Here, the right chopstick, placed above the left, directs the capsulorrhexis until the maneuver is completed. The left device now trails behind. The technique requires only three to four pulls to complete the rhexis, during which time the anterior chamber remains stable with no or minimal OVD leakage. The final diameter of the rhexis is 5.5 mm.

ADVANTAGES, EXPERIENCE WITH CAPSULORRHESIS CHOPSTICKS

The design of the capsular chopsticks enables excellent grasping of the anterior capsule. The main advantage of using the capsulorrhexis chopsticks is better anterior chamber maintenance because OVD rarely leaks from the sub-1-mm incisions. Although I prefer to use DuoVisc (Alcon Laboratories, Inc., Fort Worth, Texas), the surgeon can use his OVD of choice; both dispersive and cohesive OVDs work

well in the bimanual rhexis technique.

The idea of using two devices to create the capsulorrhexis occurred to me by chance one day during a standard MICS procedure. The nurse announced that the forceps were damaged. In the time it took her to replace them, I had managed to perform the capsulorrhexis with only my manipulators. The bimanual capsulorrhexis was efficient, and the procedure was accomplished without complications. I subsequently developed the capsulorrhexis chopsticks to use in place of the manipulators.

I have done approximately 100 cases using the chopsticks. All of these bimanual capsulorrhexis procedures were performed without complications and were completely round. The mean rhexis diameter was 5.45 mm, with a mean creation time of 28 seconds. For me, the learning curve was only 10 cases. The novelty compared with a standard capsulorrhexis is that the tear is made in the horizontal versus the vertical plane. Additionally, the surgeon must learn to use two hands to create the capsulorrhexis, a different technique from bimanual phaco. Any technique of the surgeon's preference can then be used for cataract removal.

CONCLUSION

This new bimanual rhexis technique with capsulorrhexis chopsticks is a safe and effective way to perform sub-1-mm, tridimensional capsulorrhexis. As cataract surgery incisions continue to decrease in size, we will see an increase in the number of techniques surgeons can use during MICS. The bimanual rhexis represents a new philosophy in capsulorrhexes that enhances anterior chamber stability and promotes micro-MICS. ■

TAKE-HOME MESSAGE

- Capsular chopsticks can be used in place of a bent needle or forceps.
- Two sub-1-mm clear corneal incisions allow access for bimanual rhexis creation in the horizontal plane.
- The bimanual rhexis technique allows tridimensional control in a stable anterior chamber.

Thierry Amzallag, MD, practices at the Ophthalmic Institute of Somain, France. Dr. Amzallag states that he has no financial interest in the products or companies mentioned. He may be reached at e-mail: Thierry.amzallag@institut-ophtalmique.fr.



Joel Pynson, MD, is the Director of Design Engineering, Bausch & Lomb, Toulouse, France.