

Enhancing Ectasia Screening

Corneal tomography and biomechanics measurement can increase screening accuracy.

BY RENATO AMBRÓSIO JR, MD, PhD

Careful preoperative screening is paramount for the success of refractive surgery. In the case of LASIK or PRK, it is crucial to screen patients for corneal abnormalities that, if the patient were operated on, would increase the risk of postoperative corneal ectasia. For instance, patients with keratoconus or pellucid marginal degeneration are known to have poor postoperative outcomes that commonly progress to ectasia. However, some patients with recognized ectatic risk factors remain stable many years after LASIK. Conversely, many cases of ectasia have been reported after LASIK despite patients' low risk scores on standard screening tests. We are all puzzled by this mystery.

The answer lies in achieving a more detailed characterization of the cornea to detect early forms of ectatic disease and the susceptibility to develop ectasia. I believe this level of screening sensitivity can be reached by combining corneal tomography and biomechanics analysis. These modalities are now available on the Pentacam (Oculus Optikgeräte GmbH, Wetzlar, Germany) and the Ocular Response Analyzer (ORA; Reichert, Inc., Depew, New York), respectively. These methods in combination provide greater sensitivity to detect ectasia risk and more specificity to identify good candidates among cases with suspicious findings on Placido-disc-based corneal topography and central corneal thickness measurement, the current gold standard screening protocol for refractive candidates.

Along with Placido-disc-based topography and ultrasound pachymetry, patient age, refractive correction, flap thickness, and residual stromal bed thickness are considered when assessing the risk for ectasia. Randleman et al¹ described a score system, based on these variables, that represents an improvement in our understanding of ectasia risk. Using these criteria, however, there are still more than 5% false negatives among the cases that developed ectasia after LASIK. Additionally, there is a high false-positive rate of cases that had good LASIK results despite being identified as having high ectasia risk.

In my opinion, improving sensitivity and specificity of the

screening protocol for refractive candidates requires a tomographic approach, thus analyzing the corneal architecture in 3D. Such a strategy combines anterior and posterior corneal elevation with complete pachymetric data to reconstruct corneal architecture.

Tomography with the Pentacam enables front and back elevation and pachymetric map reconstruction from limbus to limbus. The Belin Ambrósio Enhanced Ectasia Display on the Pentacam, based on tomographic elevation data from the rotating Scheimpflug camera, provides a comprehensive keratoconus screening index. Anterior and posterior elevation data are matched to a best-fit-sphere with an 8-mm fixed optical zone.

In the presence of keratoconus or ectasia, the cone will noticeably cause a steepening of the best-fit-sphere, minimizing the difference in elevation between the cone's apex and the best-fit-sphere. The Enhanced Ectasia Display takes this principle one step further with its enhanced reference surface, developed by Michael W. Belin, MD, of New York. This

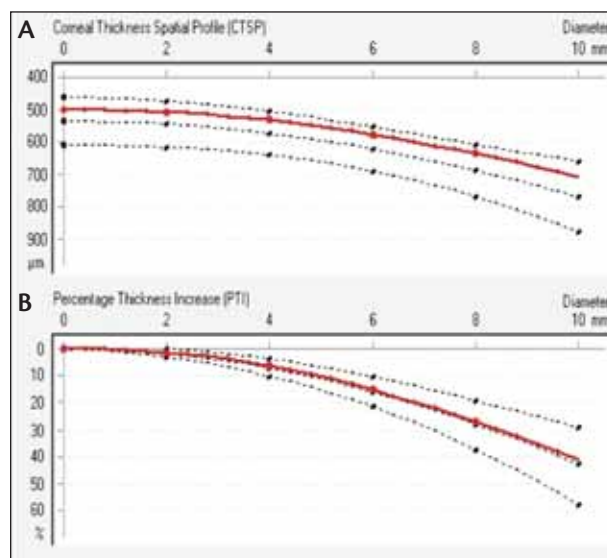


Figure 1. (A) CTSP and (B) PTI profiles from a normal thin cornea on the Pentacam's Enhanced Ectasia Display.

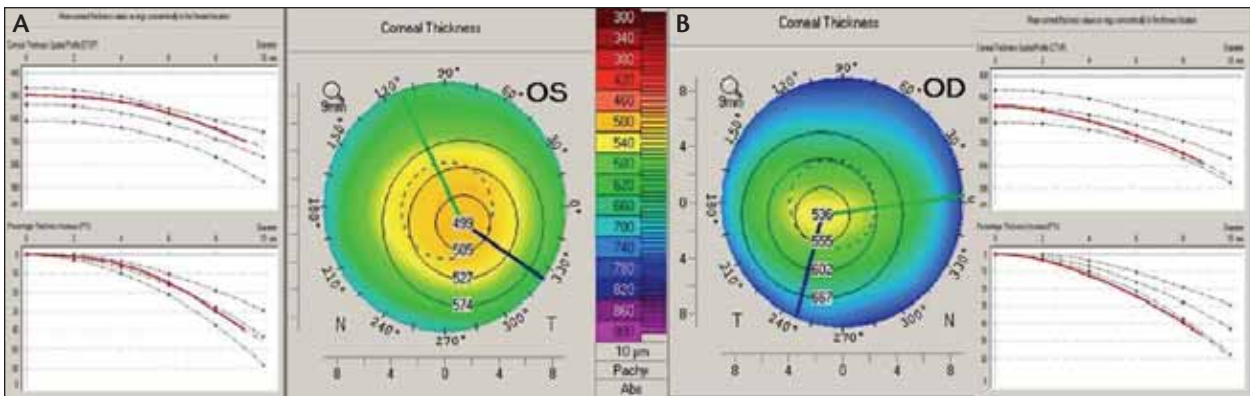


Figure 2. (A) Normal thin cornea versus (B) keratoconus. The red lines indicate the patient's corneal parameters in relation to 95% CI for the thickness profile and percentage of increase.

software calculates the reference shapes for the front and back surfaces of the cornea. Data are excluded from the 3.5-mm optical zone surrounding the cornea's thinnest point to compute the enhanced best-fit-sphere. The difference between the standard and enhanced best-fit-spheres indicates a change in elevation, which is useful to identify ectatic protrusion on the corneal surface.

Pachymetry is an excellent indicator of corneal health, identifying the true thinnest point and its location. The parameters include the apex (ie, central thickness), thinnest point, distance from apex to thinnest point, difference between apex and thinnest point, pachymetric progression index, profile curves, and asymmetry profile. The Enhanced Ectasia Display software incorporates two pachymetry profiles, the corneal thickness spatial profile (CTSP) and percentage thickness increase (PTI). Both profiles (Figure 1) are based on the physiologic concept that the cornea is a meniscus—a structure that is thinner in the center and thicker in the periphery.

The software can detect the thinnest point and calculate the rate of increase in thickness from this point outward to the periphery. We can also calculate the direction of displacement. The distance between the thinnest point of the cornea and the geometric center is significantly higher in corneas with keratoconus than in normal corneas. Additionally, ectatic corneas thin at a faster rate when compared with normal corneas.

We have defined the 95% confidence interval (CI) range for the increase in corneal thickness from the thinnest point to the limbus in the normal population. We found that the rate of increase in corneal thickness is higher in the presence of keratoconus (Figure 2). The CTSP and PTI graphs, indicating progressive thickening, depict the 95% CI and the mean norm with dotted lines so that the surgeon can compare the examined eye with the normal population parameters to detect early ectatic disease. The examined eye appears on

the graph in red; data are derived using pachymetry values from 22 concentric rings centered on the thinnest point.

It is also possible to distinguish a normal thin cornea from a thin cornea with early ectasia as well as a normal thick cornea from a thick cornea showing signs of early edema. This is possible because we consider not only the central thickness and thinnest point but how the thickness is distributed over the entire cornea. The pachymetric progression index is calculated to help in the analysis. These indexes are calculated for the average of the whole corneal volume and for the meridians with the highest and lowest rates of increase.

In the newest software release, we have also introduced regression analysis that displays the deviation-from-normality indices (normal vs keratoconic corneas; Figures 3 and 4) for front and back surfaces, pachymetry progression, and progression of increase in thickness. These new deviation (D) parameters, showing the standard deviation from the mean, are combined to help in diagnosis. Our first studies using these indices included more than 200 normal eyes and 80 eyes with keratoconus. The D parameters provided excellent separation of normal and keratoconic corneas, with greater than 95% sensitivity and specificity.

When used collectively, the tools available with the Enhanced Ectasia Display software help the surgeon to distinguish a normal cornea from a suspicious or abnormal one. This technology represents the first completely elevation-based screening device.

ORA PARAMETERS FOR BIOMECHANICS

The other component for enhanced screening is biomechanics. We have used the ORA for more than 4 years. Corneal hysteresis and corneal resistance factor are significantly different among normal and keratoconic eyes, but there is an overlap. Interestingly, the signal morphology is intuitively identified as the most important part of the data. Recently, a

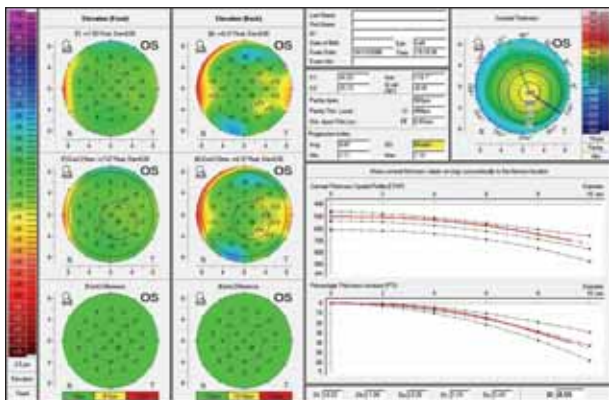


Figure 3. The D parameters in a normal thin cornea with central corneal thickness of 500 µm.

huge improvement in the ability to extract numeric metrics from the waveform signals, beyond hysteresis, has enabled better separation and less overlap. However, I am sure new metrics for the ORA and new tests for evaluating corneal biomechanics will be introduced in the near future.

PEARLS FOR USE

With the more detailed information available by combining tomography and corneal biomechanics, we can now enhance our screening approach for ectasia. We have reached the point where we can identify susceptibility to ectasia. This information is truly relevant for the surgeon to determine patients' candidacy for LASIK. Below are several pearls for use of the Pentacam's Enhanced Ectasia Display.

I consider the value of the thinnest point and its location in relation to the center of the exam (apex) and the apex thickness. The reason is that the thinnest point value is a better parameter to separate normal corneas from those with keratoconus. I also consider the average increase of thickness and the meridians of minimal and maximal progression.

The thickness profile graphs enable comparison of the examined eye with normal population values. A deviation from the mean and escape from the 95% CI lines also are important tomographic signs of suspicious corneas.

Integration of the enhanced elevation maps has also led to an improvement in diagnosis of subclinical keratoconus. For example, in a patient with asymmetric keratoconus in one eye and seemingly normal topography (ie, anterior curvature) in the contralateral eye, we typically see abnormalities

TAKE-HOME MESSAGE

- A tomographic approach analyzes the corne in 3D, with anterior and posterior corneal elevation and pachymetry.
- Enhanced screening increases sensitivity and specificity.

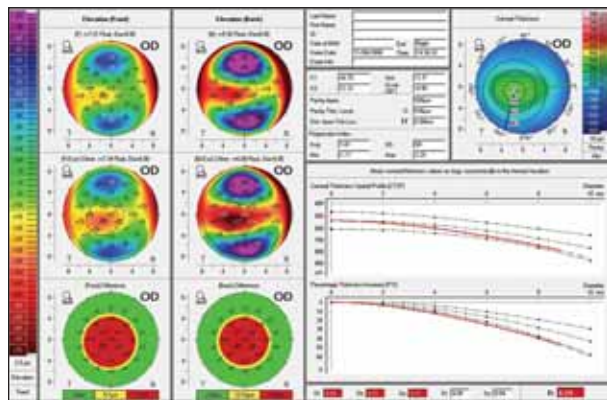


Figure 4. The D parameters in a keratoconic cornea with central corneal thickness of 536 µm.

on the Belin Ambrósio Enhanced Ectasia Display in the contralateral eye. Because the disease is bilateral by definition, a diagnosis of unilateral keratoconus is not acceptable. In such cases, although there is ectatic susceptibility, no phenotypical expression of ectasia is visible on the surface. The same concept was introduced approximately 20 years ago, when curvature maps enabled the detection of keratoconus patterns in patients with a normal corneal exam at the slit lamp and normal BCVA. Most authors refer to this as *forme fruste keratoconus*, but I consider it subclinical keratoconus.

CONCLUSION

Today's enhanced screening capabilities have increased the sensitivity and specificity of our diagnostic data. Studies at the Rio de Janeiro Corneal Tomography and Biomechanics Study group focus on identifying criteria for ectasia susceptibility, which therefore strengthens our ability to provide patients with the best possible refractive surgery outcomes. However, it is still relevant to use corneal topography to screen patients. I believe that new biomechanical tests and models are still to come, and the Pentacam's Enhanced Ectasia Display software is leading the way. I am also positive we will witness an explosion of knowledge for understanding corneal biomechanics; this will definitively impact the safety and efficacy of refractive surgery. ■

Renato Ambrósio Jr, MD, PhD, is an Associate Professor of Ophthalmology, Pontific Catholic University, Director of Cornea and Refractive Surgery, Instituto de Olhos Renato Ambrósio, Visare Personal Laser and Refracta-RIO, Rio de Janeiro, Brazil. Dr. Ambrósio states that he is a consultant to Oculus Optikgeräte GmbH. He may be reached at e-mail: renatoambrósiojr@terra.com.br.



1. Randleman JB, Trattler WB, Stulting RD. Validation of the Ectasia Risk Score System for preoperative laser in situ keratomileusis screening. Am J Ophthalmol. 2008;145(5):813-818.