

Technology Required for Quality Cataract Surgery

The benefits of adopting state-of-the-art equipment are plentiful.

BY AMAR AGARWAL, MS, FRCS, FRCOPHTH; AND DHIVYA ASHOK KUMAR, MD

Surgical techniques in cataract surgery are becoming increasingly sophisticated, and cataract surgical adjuncts are more diversified. Today, the objective in cataract surgery is to achieve the patient's preferred visual outcome with minimal trauma. The size of the cataract incision has continually decreased—from the large incisions used for intracapsular cataract extraction, to the slightly smaller ones used in extracapsular cataract extraction (ECCE), and finally to the present-day small incisions used in phacoemulsification.

With the evolution from large-incision cataract procedures of olden time, surgeons have gained access to highly sophisticated phacoemulsification techniques.¹ Techno-

logical developments have allowed surgeons to perform cataract surgery in less time and on an outpatient basis. This article highlights the technologies that permit quality cataract surgery today and the benefits of adopting such state-of-the-art technologies, including smaller incisions, shorter surgical time, and fewer postoperative complications.

DEVELOPMENTS

Phacoemulsification. The introduction of phacoemulsification tremendously reduced suture-related astigmatism and inflammation after cataract surgery. The initial steps of conventional phacoemulsification include continuous curvilinear capsulorhexis, hydrodis-

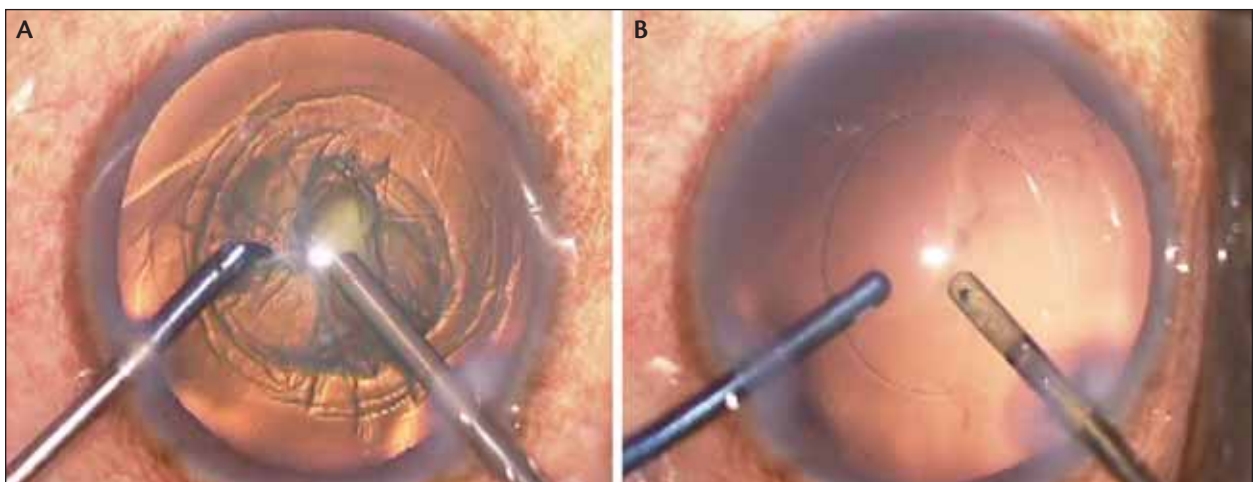


Figure 1. (A) Microphakontomy performed with a 700-µm phaco needle and 700-µm irrigating chopper. (B) Bimanual irrigation and aspiration done with a 700-µm bimanual I/A set.

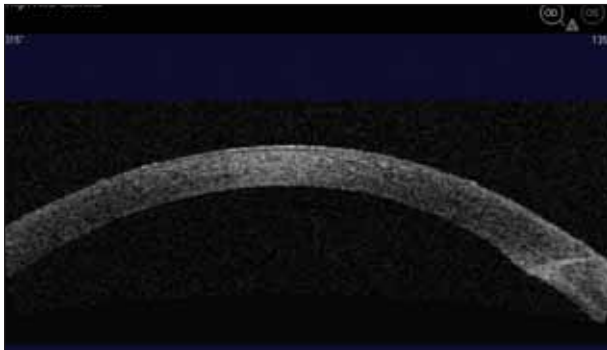


Figure 2. Anterior segment OCT cross-sectional image of the microphakonit wound showing good endothelial alignment.

section, and hydrodelineation. These are followed by phacoemulsification of nucleus material and removal of cortex with aspiration.

Combined IOL implantation. Implanting the IOL in the same sitting provides early visual rehabilitation. Additionally, the introduction of superior ophthalmic viscosurgical devices (OVDs) maintains the anterior chamber intraoperatively.² Foldable IOLs that pass through smaller incisions are new additions to our surgical armamentarium that further save procedure time. Hence, it has become mandatory that every cataract surgeon be well trained in phacoemulsification.

Microincision cataract surgery (MICS). Advances in phaco platforms and techniques, along with the invention of foldable IOLs, made possible clear corneal incisions of less than 3 mm.³⁻⁷ MICS continues to garner attention because it induces less postoperative astigmatism compared with conventional phacoemulsification. Additionally, faster wound healing, less fluid ingress (and resultant reduced risk of infection), less postoperative leakage, a shallow anterior chamber, fewer suture-related complications, and therefore less chance of inflammation have made MICS popular.

Using 700- μ m surgical instruments (Figure 1), we reported creation of the smallest cataract incisions on record in 2005. We termed the procedure *microphakonit* to differentiate it from the 0.9-mm phakonit³⁻⁷ previously reported in 1998. Incisions used for microphakonit are small and self-sealing (Figure 2), making their chance of

TAKE-HOME MESSAGE

- Use of state-of-the-art technologies can reduce incision size, surgery time, and postoperative complications.
- New IOL technologies require proper patient selection and accurate IOL calculations.
- Every surgeon should properly equip himself for managing complications.

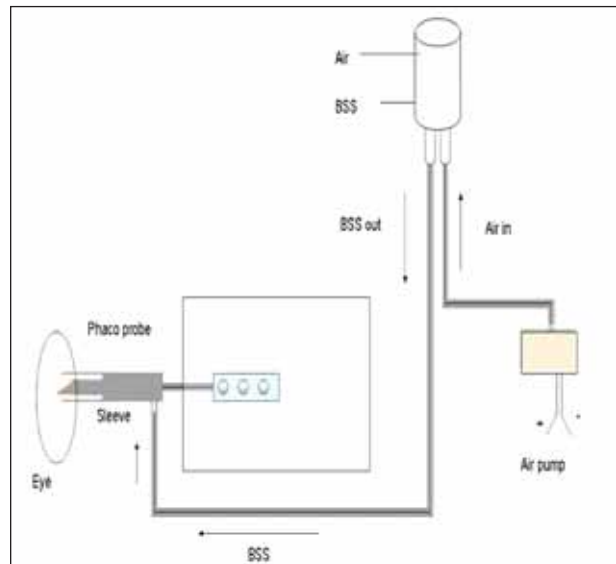


Figure 3. Schematic diagram of the mechanism of action of the air pump for gas-forced infusion.

opening as a result of lid or ocular movements negligible. Therefore, postoperative entry of periocular bacteria into the eye is only a remote possibility. Recent phaco machines have built-in settings for MICS procedures that make surgery even easier.

TECHNOLOGIES

Avoiding surge. Intraoperative surge can be reduced by using an air pump (ie, gas-forced infusion; Figure 3) during phaco.⁸ Young phaco surgeons starting their practice and within their learning curve can highly benefit from this technology. The automated air pump is used to push air into the infusion bottle, increasing the pressure with which the fluid flows into the eye. This increases the steady-state pressure of the eye and keeps the anterior chamber deep and well maintained during the entire procedure. It makes phacoemulsification and MICS procedures relatively safe by reducing surge, even at high vacuum levels. The Stellaris (Bausch & Lomb, Rochester, New York) has a built-in air pump.

Measurements. The IOLMaster (Carl Zeiss Meditec, Jena, Germany) is currently used in tertiary hospitals to calculate IOL power. This technology can aid in preventing postoperative refractive surprises. Anterior segment optical coherence tomography (OCT), a noninvasive imaging technique, also has numerous indications in cataract surgery.⁹ Aspects of wound architecture such as epithelial and endothelial alignment, stromal thickness, presence of Descemet's detachment, and anterior segment details can be visualized easily postoperatively. Even in eyes with postoperative corneal edema in which

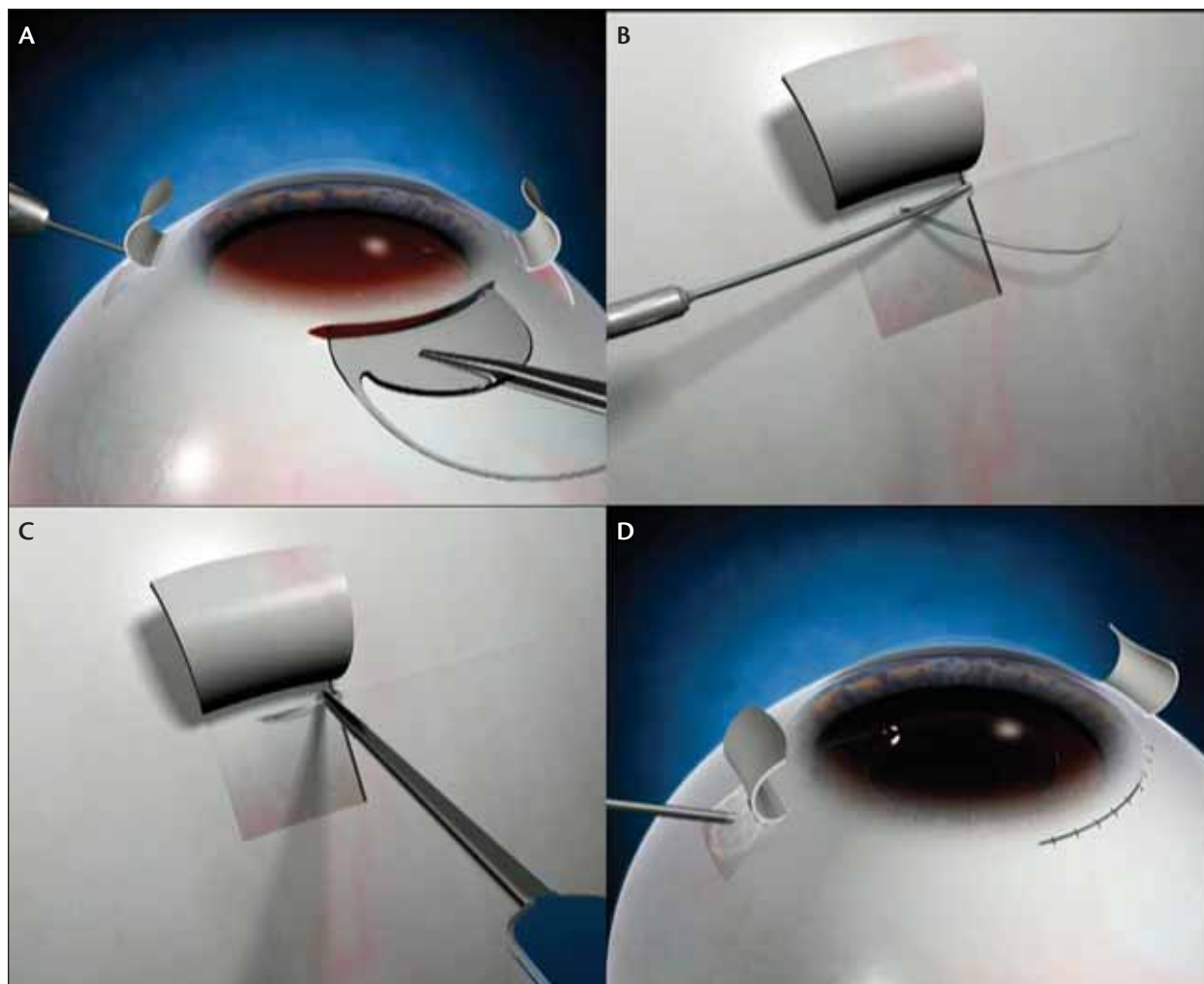


Figure 4. The glued IOL. (A) Two partial-thickness scleral flaps are made 180° apart, and a three-piece IOL is introduced through the limbal incision. The haptic is externalized through the sclerotomy, beneath the flaps. (B) A scleral tunnel is created with a 26-gauge needle. (C) The IOL haptic is tucked into the tunnel. (D) Fibrin glue is used to close the scleral flaps.

the anterior chamber is not clearly visible, early anterior chamber inflammation can be detected with OCT.¹⁰

Specular microscopy should be routinely performed preoperatively to evaluate the endothelial status of the cornea and its ability to withstand surgical trauma. Corneal topography analysis with the Orbscan II (Bausch & Lomb) identifies preoperative astigmatism and therefore aids in placement of the cataract incision.

IOL technology. Multifocal IOLs have recently gained popularity. Patient selection and accurate IOL power calculation should be emphasized when opting for multifocal IOL implantation. Refractive and diffractive multifocal IOLs are available, and it is the surgeon's job to select the ideal patient for this type of lens.

Foldable IOLs that pass through incisions as small as 2.2 mm, namely microincision and thin optic lenses, can

be used in MICS.⁴ Aspheric IOLs are recommended to reduce postoperative spherical-aberration-induced poor quality of vision. In IOL models with sharp posterior or optic edges, studies have shown no substantial differences in posterior capsular opacification (PCO) prevention, regardless of IOL material.¹¹ The sharp posterior optic edge is the main factor in PCO prevention.

PREVENTING INFECTIONS

Preoperative antibiotics. Quality cataract surgery is not achieved unless the patient is free of any postoperative infection. We recommend routine use of preoperative antibiotics; commonly, the antibiotic of choice is a topical fluoroquinolone. Preoperative cleaning of the surgical field with povidone-iodine; appropriate use of aseptic methods, including careful draping and proper

The anterior segment surgeon is required to be well trained in managing complications and should be equipped accordingly.

selection of anesthesia; intra- and postoperative chemoprophylaxis; and selection of the optimal clear corneal wound design and construction reduce the risk of postoperative infection.

Early detection. All anterior segment surgeons should be well equipped to detect early signs of postoperative inflammation and endophthalmitis. Early diagnosis and prompt treatment can prevent loss of BCVA.

COMBATING INTRAOPERATIVE COMPLICATIONS

Posterior capsule. The incidence of posterior capsular complications is related to the type of cataract and condition of the eye; incidence increases with the grade of cataract and is influenced by the level of experience of the surgeon. Timely recognition and planned management, depending upon the stage of surgery during which the posterior capsular tear has occurred, is required to ensure an optimal visual outcome. Reducing the phacoemulsification machine setting parameters, using dry aspiration, performing anterior vitrectomy in eyes with vitreous loss, and timely conversion to ECCE can prevent inadvertent complications.

In the presence of a posterior capsular tear with an otherwise good capsular bag, the IOL can be placed in the bag. When the tear is large, consider using scleral fixation of a posterior chamber or anterior chamber IOL. The glued IOL (Figure 4) is a new technique that can be performed in eyes without capsular support.¹³ Three-piece foldable IOLs or one-piece rigid IOLs can be easily implanted using this technique.

Pupil. If zonular dialysis is noted on the table, the surgeon can use capsular tension rings for stabilization.¹ A persistent nondilating pupil can be enlarged with iris hooks or retractors. The Malyugin Ring (MicroSurgical Technology, Redmond, Washington) can be used to dilate the pupil intraoperatively.¹²

The anterior segment surgeon is required to be well trained in managing complications and should be equipped accordingly. Good patient selection for phacoemulsification is necessary for a good postoperative outcome. Patients with poor endothelial cell counts or hard cataracts should be seen as high-risk cases. Endothelial decompensation and corneal edema can be

prevented by employing careful patient selection, using a superior OVD to coat the endothelial surface, adding an air pump to the infusion bottle, and avoiding use of excessive ultrasound power in the anterior chamber. Moreover, postoperative inflammation can be reduced by avoiding excessive intraoperative iris manipulation.

CONCLUSION

With recent modifications in cataract surgery have come new technological developments; it is now possible to provide optimal postoperative outcomes to our patients. However, factors such as utility, cost, and accessibility must be considered in some circumstances. With recent advances and the increasing expectations of patients, every phaco surgeon should be equipped to perform quality cataract surgery by offering adequate technology to his patients. ■

Amar Agarwal, MS, FRCS, FRCOphth, is in private practice at Dr. Agarwal's Eye Hospital and Eye Research Centre, Chennai, India. Dr. Agarwal states that he is a consultant to Abbott Medical Optics Inc., Bausch & Lomb, and STAAR Surgical. He may be reached at tel: + 91 44 2811 6233; fax: + 91 44 2811 5871; e-mail: dragarwal@vsnl.com.



Dhivya Ashok Kumar, MD, practices at Dr. Agarwal's Eye Hospital and Eye Research Centre, Chennai, India. Dr. Kumar states that she has no financial interest in the products or companies mentioned. She may be reached at tel: +91 44 2811 6233; fax: +91 44 2811 5871; e-mail: susruta2002@gmail.com.

1. Agarwal A. Phaco Nightmares: Conquering cataract catastrophes. Thorofare, New Jersey: Slack Inc.; 2006.
2. Tetz MR, Holzer MP, Lundberg K, Auffarth GU, Burk ROW, Kruse FE. Clinical results of phacoemulsification with the use of Healon5 or Viscoat. J Cataract Refract Surg. 2001;27:416-420.
3. Agarwal A, Agarwal S, Agarwal A, et al. Phakonit: phacoemulsification through a 0.9 mm incision. J Cataract Refract Surg. 2001;27:1548-1552.
4. Pandey S, Werner L, Agarwal A, et al. Phakonit: Cataract removal through a sub-1.0 mm incision with implantation of the ThinOptX rollable IOL. J Cataract Refract Surg. 2002;28:1710-1713.
5. Agarwal A, R Trivedi, Jacob S, Agarwal. Microphakonit: 700 micron cataract surgery. Clin Ophthalmol. 2007;1(3):323-325.
6. Alio J, Rodriguez-Prats JL, Galal A, et al. Outcomes of microincision cataract surgery versus coaxial phacoemulsification. Ophthalmology. 2005;112(11):1997-2003.
7. Agarwal A, Agarwal S, Agarwal A. Phakonit: A new technique of removing cataracts through a 0.9 mm incision. In: Agarwal A, Agarwal S, Agarwal A, eds. Phacoemulsification, laser cataract surgery and foldable IOLs. New Delhi, India: Jaypee Brothers; 1998:139-143.
8. Agarwal A, Agarwal S, Agarwal A. Antichamber collapse. J Cataract Refract Surg. 2002;28:1085-1086.
9. Agarwal A, Kumar DA, Jacob S, Agarwal A. In vivo analysis of wound architecture in 700 microm microphakonit cataract surgery. J Cataract Refract Surg. 2008;34(9):1554-1560.
10. Agarwal A, Ashokkumar D, Jacob S, Agarwal A, Saravanan Y. High-speed optical coherence tomography for imaging anterior chamber inflammatory reaction in uveitis: clinical correlation and grading. Am J Ophthalmol. 2009;147(3):413-416.
11. Nishi O, Nishi K, Osakabe Y. Effect of intraocular lenses on preventing posterior capsule opacification: design versus material. J Cataract Refract Surg. 2004;30(10):2170-2176.
12. Chang DF. Use of Malyugin pupil expansion device for intraoperative floppy-iris syndrome: results in 30 consecutive cases. J Cataract Refract Surg. 2008;34(5):835-841.
13. Agarwal A, Kumar DA, Jacob S, et al. Fibrin glue-assisted sutureless posterior chamber intraocular lens implantation in eyes with deficient posterior capsules. J Cataract Refract Surg. 2008;34:1433-1438.